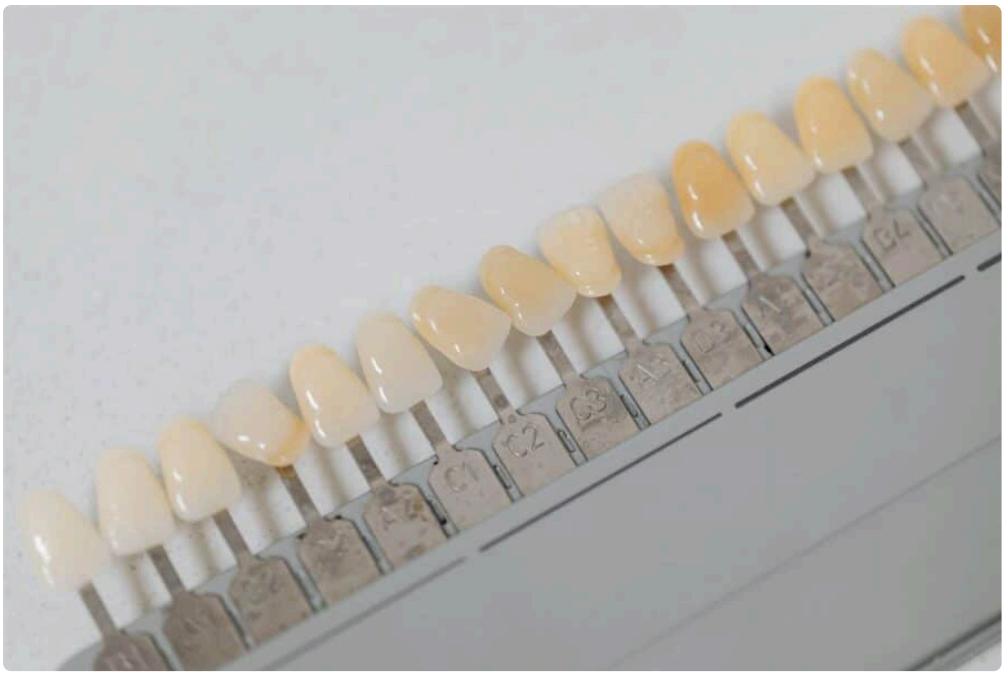

A damaged tooth can look dramatic and still be repairable. The opposite is also true. I have seen tiny cracks turn into major problems because someone waited too long, and I have seen teeth with a surprising amount of visible damage saved because treatment happened within the right window. That is why the answer to this question is not a simple yes or no. An emergency dentist in Santa Clarita, CA can often save a damaged tooth, but timing, the type of injury, the depth of the damage, and the condition of the surrounding tissues all matter.

When people hear “save the tooth,” they often think only of pain relief. In practice, saving a tooth means preserving as much healthy structure as possible, protecting the nerve when feasible, stabilizing the bite, and reducing the odds of extraction later. Sometimes that means a filling and a careful polish. Sometimes it means a root canal and crown. Sometimes it means the tooth cannot be saved, but the dentist can still save the bone, the gum architecture, and the space, which makes a future replacement far easier and more predictable.

The first few hours after trauma or sudden tooth pain are especially important. Teeth are not like fingernails. They do not simply grow back if a large piece breaks off. But the mouth has more repair options than most people realize, especially when an experienced emergency team evaluates the damage quickly.

What counts as a dental emergency

Not every chipped tooth needs same-day care, but many do. The challenge is that patients rarely know, just by looking, whether the damage is cosmetic or serious. A sharp edge might only need smoothing, while a small-looking fracture could extend into the dentin or even the root. Swelling, bleeding around the gumline, a loose tooth, and sensitivity to cold or pressure all raise the stakes.

A true dental emergency usually involves one or more of these issues:

- severe or escalating pain
- a tooth that is cracked, fractured, loose, or knocked out
- swelling, pus, or signs of infection
- uncontrolled bleeding
- difficulty biting because the tooth no longer lines up correctly

That list is short, but the real-world situations vary. A teenager catches an elbow during basketball and chips a front tooth. A parent bites down on an olive pit and splits a molar. An older adult with a large, aging filling wakes up with half the tooth in their hand. All three may need urgent treatment, even though the causes are completely different.

The kinds of damage that can often be repaired

A lot depends on where the tooth is injured. Enamel damage alone is the most straightforward. Enamel is the outer shell, and if the chip is shallow, the dentist may be able to smooth the edge, place bonding, or use a veneer later if esthetics matter. These are the cases that tend to recover quickly.

Once the fracture reaches dentin, the situation becomes more urgent. Dentin is softer, more porous, and connected to the nerve through microscopic tubules. That is why patients often describe a broken tooth as “suddenly sensitive to air.” A dentin-level fracture may still be very repairable, but it needs sealing and protection before bacteria work deeper into the tooth.

If the pulp is involved, meaning the nerve tissue is exposed or inflamed beyond recovery, the tooth may still be saved with root canal treatment followed by a crown or other restoration. Patients are often surprised to hear that a tooth with nerve damage can remain in the mouth for years, even decades, if the root structure is sound and the final restoration is well done.

Even a tooth that has been partially dislodged can sometimes be repositioned and splinted. This is common after falls, sports injuries, or car accidents. The key is fast evaluation. The longer a tooth stays out of position, the more complicated healing becomes.

When time makes the difference

If there is one pattern emergency dentists see repeatedly, it is this: the delay causes the bigger problem. A crack that might have needed bonding on Friday turns into a weekend abscess by Monday. A knocked-out tooth that could have had a fighting chance is stored dry in a tissue for two hours and loses that chance.

A tooth is easier to save when the dentist can intervene before bacteria colonize the pulp, before the fracture line propagates further, and before the bite keeps flexing the damaged area. Teeth under chewing force behave like stressed beams. Each bite can widen a crack, especially in molars with old fillings or cusps that have already thinned out over time.

For a knocked-out permanent tooth, minutes matter. If the tooth is clean, handling it only by the crown and placing it back into the socket can be ideal. If that is not possible, storing it in milk or a tooth preservation solution is usually far better than letting it dry out. It should not be scrubbed aggressively. The cells on the root surface are delicate, and once they are badly damaged, successful reattachment becomes much less likely.

For a cracked or broken tooth that is still in place, quick care can preserve structure that would otherwise be lost. The dentist can place a temporary protective material, adjust the bite, control pain, and decide whether the tooth needs a crown, root canal, splinting, or referral to a specialist.

How an emergency dentist decides whether a tooth can be saved

Patients often want an answer immediately, and understandably so. Still, a responsible dentist does not promise too much based on appearance alone. The tooth needs to be tested and imaged. That usually includes an exam,

X-rays, checking mobility, tapping the tooth, evaluating the gums, and looking for signs that the fracture extends below the gumline or into the root.

A few details carry a lot of weight. One is whether the crack is restorable. If enough healthy tooth remains above Smyle Dental Newhall Emergency Dentist Santa Clarita, CA the bone level, the dentist can often rebuild it. Another is whether the root is intact. A vertical root fracture, especially in a back tooth, carries a much poorer prognosis than a crown fracture above the gumline. Periodontal support matters too. A severely loose tooth with significant bone loss is harder to save than a stable tooth with a similar visible break.

Pulp testing also helps, although immediately after trauma the results can be misleading. A tooth may not respond normally right away and still recover. This is one reason follow-up visits matter. Emergency care is often the first chapter, not the whole story.

In Santa Clarita, where families, commuters, athletes, and active older adults all make up a large part of the patient population, emergency dental injuries can come from very ordinary moments. A rushed breakfast before work. A trail fall. A youth sports collision. The mechanism matters because it hints at what the dentist should look for. A blow to the front teeth raises concern for displacement and root injury. A sudden bite on something hard often suggests cracked tooth syndrome or cusp fracture in a molar.

Common treatments that help save a damaged tooth

The treatment plan depends on the diagnosis, but the goal is usually to preserve function while preventing further breakdown. In practical terms, that can range from very conservative care to more involved reconstruction.

Bonding works well for small to moderate chips, especially in front teeth. It can often be done in one visit and gives a good cosmetic result when the fracture is limited. For larger defects, especially where chewing forces are high, a crown may offer better long-term protection.

When the nerve is irreversibly inflamed or infected, root canal therapy can remove diseased tissue and retain the tooth. This is often paired with a crown for back teeth because a root canal treated molar without cuspal coverage is more vulnerable to fracture later. That trade-off is important. Root canal treatment may save the tooth, but the job is not really finished until the tooth is protected from the force that damaged it in the first place.

If the tooth has shifted or loosened after trauma, splinting can stabilize it while the surrounding ligament heals. Think of it as a controlled rest period for the tooth. The dentist bonds the injured tooth to neighboring teeth for a limited time, then reevaluates healing and vitality.

Sometimes the most valuable service an emergency dentist provides is judgment. Not every damaged tooth benefits from aggressive rescue. If the fracture extends far below the gumline, if the root is split, or if the supporting bone is badly compromised, extraction may be the healthier option. Patients usually appreciate candor when the explanation is clear. Saving a hopeless tooth can cost more time, more pain, and more money, only to end in extraction months later.

Cracked teeth are especially tricky

Cracks are among the hardest problems in emergency dentistry because they are not always easy to see. A patient may describe sharp pain when releasing a bite, fleeting cold sensitivity, or a vague ache that comes and goes. The tooth might look almost normal. Yet the internal stress lines can be significant.

A simple cracked cusp in a molar is often manageable. If the damaged cusp is removed and the tooth is restored before the crack travels deeper, the outcome is usually favorable. A crack that extends into the pulp may still be treatable, often with root canal therapy and a crown. But once a crack runs down the root, prognosis worsens sharply.

This is where delay causes real damage. Patients often try to “chew on the other side” for a few weeks, hoping the pain will settle. Meanwhile, each meal puts torque on the compromised tooth. What might have been a crown case can become an extraction case.

What happens if the tooth cannot be saved

There is a practical fear behind this question, and it is not just about the immediate injury. People worry about appearance, speech, cost, and whether losing one tooth will start a chain reaction. Those are reasonable concerns.

If the tooth is not salvageable, emergency treatment still matters because it controls infection, protects the socket, preserves bone when possible, and sets up the next step properly. For some patients that next step is an implant. For others it may be a bridge or a removable option. The right choice depends on age, health, bone quality, budget, bite forces, and how many adjacent teeth are involved.

Losing a tooth is disappointing, but it is not the same as losing control of the situation. A thoughtful emergency dentist can explain what failed, what can still be preserved, and how to avoid a rushed replacement decision. That conversation is often just as important as the procedure itself.

What to do before you get to the office

The period between injury and treatment matters more than most people think. A few calm steps can improve the odds of saving the tooth and reduce discomfort on the way to the appointment.

- if a permanent tooth is knocked out, hold it by the crown, not the root, and keep it moist in milk or a tooth-saving solution
- if a piece breaks off, bring the fragment with you, sometimes it can help with repair
- rinse gently with water and use clean gauze for light pressure if there is bleeding
- apply a cold compress to the face in 10 to 15 minute intervals for swelling
- avoid chewing on the injured side and skip very hot, very cold, or very hard foods

There is one point worth stressing. Pain level is not a reliable measure of severity. Some badly injured teeth hurt surprisingly little at first, especially if the nerve has been damaged. Other teeth throb intensely and still turn out to be very repairable. Do not use pain alone to decide whether to wait.

Children, teens, and adults do not heal the same way

Age changes the equation. In children and teens, a tooth with an incompletely formed root may have different treatment options than a fully mature adult tooth. Dentists sometimes try especially hard to preserve vitality in younger teeth because continued root development can improve long-term strength. That can mean pulp capping or other conservative measures when appropriate.

Adults with extensive dental work present a different set of problems. Large old fillings weaken cusps. Prior root canal treatment changes how the tooth responds to trauma. Bruxism, or grinding, adds another layer of force

that can turn a modest crack into a major fracture. An emergency dentist has to consider the tooth's history, not just the fresh injury.

Older adults may also have root surface exposure from gum recession, medications that affect saliva, or brittle restorations that have lasted for years but are nearing the end of their lifespan. In these cases, saving the tooth may still be possible, but the restoration plan needs to reflect the whole mouth, not just the emergency.

The role of imaging and follow-up

A patient often feels better once the pain is under control, but that does not mean the tooth is out of danger. This is where follow-up becomes important. A traumatized tooth can change over time. Nerve tissue may recover, remain inflamed, or gradually die. Root resorption, discoloration, or delayed mobility can show up later.

X-rays taken at the emergency visit are essential, but they do not always reveal every fracture on day one. Additional imaging or later comparison films may be needed. In some cases, cone beam imaging helps clarify a root fracture or assess the extent of damage. Not every office needs to start there, but it is a valuable tool when standard films and symptoms do not line up neatly.

The best emergency care combines decisive first treatment with honest uncertainty where uncertainty exists. A dentist may say, "I think we can save this tooth, but I need to see how the nerve responds over the next few weeks." That is not hedging. It is good clinical judgment.

Why location and access matter in a true dental emergency

When someone is searching for an Emergency Dentist Santa Clarita, CA, they are usually not planning ahead on a quiet afternoon. They are in pain, holding an ice pack, or trying to calm a child with a broken front tooth. In those moments, access matters. Same-day availability, after-hours guidance, digital imaging, and a team used to handling urgent cases can make a real difference.

There is also value in local follow-through. Dental emergencies rarely resolve in a single snapshot. A Santa Clarita patient may need a temporary repair today, a definitive crown in a few weeks, and vitality monitoring for several months after trauma. Being able to return to the same office for continuity often leads to better decisions and less confusion.

The real answer

Yes, an emergency dentist can often save a damaged tooth, sometimes even when the situation looks alarming. Teeth that are chipped, cracked, partially dislodged, or painfully broken are frequently restorable if treated promptly and appropriately. The best outcomes usually come when the patient seeks help early, protects the tooth on the way in, and follows through with the full treatment plan afterward.

The harder truth is that not every tooth is savable, and not every dramatic-looking injury is the same. What matters is not panic or optimism, but a fast, skilled assessment. If you are dealing with sudden tooth trauma or severe dental pain, the smartest move is not to guess. It is to get the tooth evaluated while there is still something meaningful to save.

Smyle Dental Newhall
23754 Newhall Ave
Santa Clarita, CA 91321, United States
+16612559200

FAQ About Emergency Dentist Santa Clarita, CA

Will the ER do anything for dental pain?

An emergency department can assess serious complications and provide temporary care, but it usually cannot provide definitive dental treatment such as a filling or root canal. A dentist needs to identify and treat the cause. Call 911 or seek emergency medical care for difficulty breathing or swallowing, major facial injury, or uncontrolled bleeding.

What qualifies as a dental emergency?

A knocked-out permanent tooth, severe or persistent dental pain, swelling, and a broken tooth with pain need prompt professional assessment. Contact a dentist immediately for guidance on how urgently to be seen. Rapidly spreading swelling or swelling that affects breathing or swallowing requires emergency medical care.

What to do if I have a dental emergency in the middle of the night?

Call your dentist's office for after-hours instructions. Smyle Dental Newhall can be reached at (661) 255-9200; confirm when treatment is available. Do not wait for the office to open if you have trouble breathing or swallowing, uncontrolled bleeding, or a major facial injury. For a toothache while arranging dental care, gently rinse with warm water and avoid putting aspirin directly on the tooth or gums.